

Ganglion cell complex and nerve fibre layer in hypertension and normal-tension glaucoma

Jan Lestak^{1,2,3*}, Elena Nutterova¹, Nada Jiraskova³ and Leos Navratil²

2. JL Clinic, V Hurkach 1296/10, Prague, Czech Republic

3. Faculty of Biomedical Engineering, Czech Technical University in Prague, Czech Republic

4. Faculty of Medicine in Hradec Kralove, Charles University, Czech Republic

Abstract

Objective: The goal of the work was to compare the values of the ganglion cell complex (GCC) and the retinal nerve fibre layer (RNFL) in the same eye. Furthermore, to determine whether there is any correlation between the GCC and RNFL in the same altitudinal half of the retina. An additional goal was to determine whether there is any correlation between the GCC, RNFL and changes in visual fields (PD-pattern defect and OD-overall defect). The final aim was to carry out these investigations in both hypertension (HTG) and normal-tension glaucomas (NTG).

Patients and methods of examination: In the HTG group, there were 25 patients. This comprised 12 females with an average age of 53.25 (34-69 years) and 13 males with an average age of 60.38 (37-74 years). The second NTG group consisted of 17 females with an average age of 55.35 (25-75 years) and 8 males with an average age of 55.5 (32-69 years). Inclusion criteria were the following: visual acuity of at least 1.0 after possible correction smaller than +/-3 dioptres. Changes in visual fields were uniform in all patients and related to the incipient glaucoma disease. There were no other eye or neurological examinations performed. In the NTG patients, the diagnosis was confirmed by electrophysiological examination. GCC layer thickness was measured using the SD-OCT RTvue-100. A similar procedure was also applied to the RNFL. The visual field was examined by the fast threshold program of the Medmont M 700 device.

Results: In patients with HTG, the GCC superior value was statistically significantly lower than the GCC inferior value. However, this difference is not clinically significant (87.65 versus 88.75, $p=0.03$). Also, no statistically significant difference was found between the RNFL values from the upper half versus the lower half of the optic disk. With regard to the correlation between the GCC and RNFL values in the upper halves of the retina, we found medium-strong and statistically significant correlation ($r=0.36$) in HTG. An even stronger correlation was found when comparing the lower retinal halves ($r=0.65$). In the group of patients with NTG, there was no statistically significant difference between the GCC superior and the GCC inferior values. Similarly, we did not find any statistically significant difference between the RNFL from the upper half of the optic disk versus the RNFL from the lower half. By comparison of the GCC, RNFL and changes in visual fields, we found medium-strong correlation only in patients with NTG between PD and GCC superior ($r=-0.41$, $p=0.003$) and PD and RNFL superior ($r=-0.4$, $p=0.005$) and also between PD and RNFL inferior ($r=-0.3$, $p=0.03$).

In HTG, we did not find any statistically significant correlation.

Conclusion: Examination of the GCC and RNFL showed medium-strong correlation for both NTG and HTG patients. Examination of the GCC, RNFL and PD showed medium-strong correlation only in patients with NTG. These conclusions indicate the existence of two different diseases which also require different treatments.

Keywords: GCC, RNFL, visual field, hypertension glaucoma, normal-tension glaucoma
*Corresponding author: Jan Lestak, doc, MD, PhD, MSc, MBA, LLA, DBA, FEBO, FAOG
JL Clinic, V Hurkach 1296/10, 158 00 Prague 5, Czech Republic, E-mail:
lestak@seznam.cz

Introduction

Glaucoma is still defined as a chronic progressive neuropathy with excavation and atrophy of the optic disk and subsequent changes in the visual field. This definition does not satisfy the current knowledge and requires correction. In a more recent concept, glaucoma may be defined as a disease where the progressive loss of ganglion cells of the retina and their axons is manifested as changes in the visual field with atrophy and excavation of the optic disk. However, even such a definition which emphasises the prominence of the retinal ganglion cells' damage over the retinal axons' damage is not comprehensive, because it does not simultaneously highlight the damage of ganglion cells in subcortical and cortical areas of the brain. The current definition does not distinguish between hyper- and normal-tension glaucomas.

NTG differs in several aspects in comparison with HTG: in addition to the levels of intraocular pressure, there are changes in the visual field which, in NTG, have more impact on the central part and have deeper defects in sensitivity [1, 12, 13]; in NTG, fibres are more damaged in the central part of the retina, the damage has a focal character [18] and the excavation is usually wider and deeper [4]; in addition, patients with NTG suffer from vasospasms [6], nocturnal systemic hypotension, reduction of ocular pulse amplitude, fluctuations in ocular perfusion pressure [14, 15, 17], narrow retinal veins and even impairment of blood rheological properties [8, 9], etc.

In HTG, the ganglion cells' damage occurs diffusely over the entire retina. As a consequence, their axons die off. The duration of the time between these changes and the alterations in subcortical and cortical visual areas of the brain is not exactly known.

In NTG, the electrical response of ganglion cells is relatively good in comparison to HTG. Alterations are also present in the visual pathway [11]. Based on this knowledge, it may be assumed that, in HTG, there will be a diffuse decrease of the GCC and that changes in the RNFL will be secondary in the early stages of the disease. Since the visual field corresponds with the entire visual path, the GCC and RNFL results may not correlate with them in the later stages.

In NTG, the GCC should be mainly less damaged in the early stages in comparison to the RNFL which should forerun the GCC changes.

Based on these hypotheses, we determined the goals of our work: to compare values from the upper half versus the lower half of the same eye and to determine whether these values are different, for both the GCC and RNFL. Furthermore, our goal was to determine whether there is any correlation between the GCC and RNFL in the same half of the retina.

A further goal was to determine whether there is any correlation between the GCC, RNFL and changes in visual fields (PD-pattern defect and OD-overall defect). The final aim was to carry out these investigations in both the HTG, as well as the NTG group.

Material and methods

In the HTG group, there were 25 patients. This comprised 12 females with an average age of 53.25 (34-69 years) and 13 males with an average age of 60.38 (37-74 years). The second NTG group consisted of 17 females with an average age of 55.35 (25-75 years) and 8 males with an average age of 55.5 (32-69 years).

Inclusion criteria were the following: visual acuity of at least 1.0 after possible correction smaller than +/-3 dioptres (19). Changes in visual fields were approximately uniform in all patients and related to the incipient disease. There were no other eye or neurological examinations performed.

In the NTG patients, the diagnosis was confirmed by electrophysiological examination. GCC layer thickness was measured using the SD-OCT RTvue-100. A similar procedure was also carried out for the RNFL. The visual field was examined by the fast threshold program of the Medmont M 700 device. We evaluated both the pattern defect (PD) and the overall defect (OD). See Tables 1 and 2.

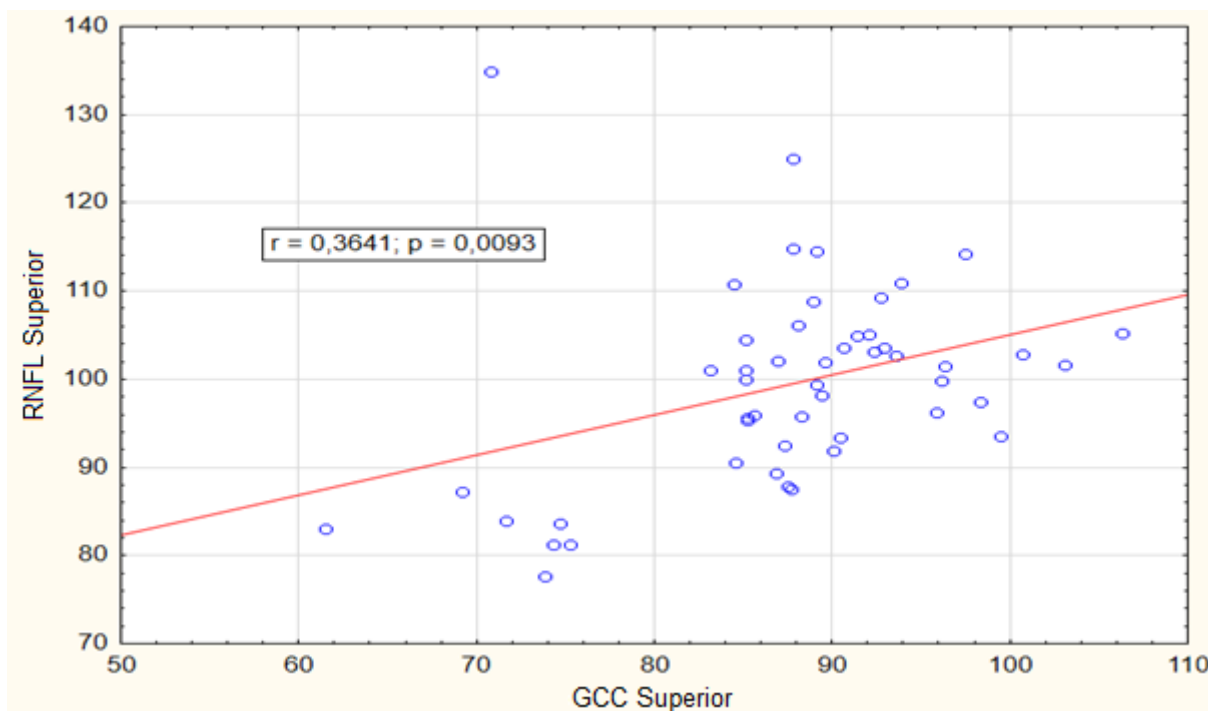
Results

In patients with HTG, the GCC superior value was statistically significantly lower than the GCC inferior value. However, this difference is not clinically significant (87.65 versus 88.75, $p=0.03$). Also, no statistically significant difference was found between the RNFL values from the upper half versus the lower half of the optic disk.

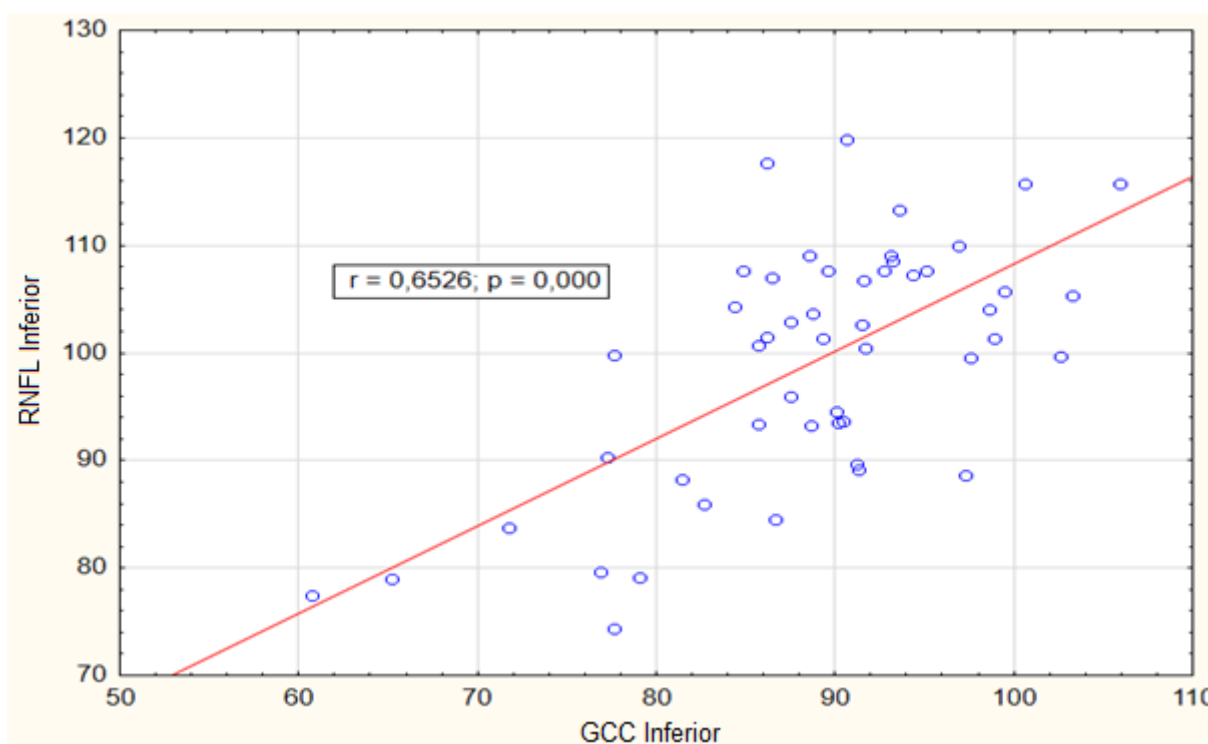
With regard to the correlation between the GCC and RNFL values in the upper halves of the retina in HTG, we found medium-strong and statistically significant positive correlation ($r=0.36$), i.e. the higher GCC, the higher RNFL. See Plot 1. Even stronger correlation was found when comparing the lower retinal halves ($r=0.65$). See Plot 2.

| HTGI | | | | | | | | | | | | |
|------------|-----------------|-----------------|-----------------|-----------------|------------------|------------------|------------------|------------------|-------|-------|-------|-------|
| Sex / year | GCC RE superior | GCC RE inferior | GCC LE superior | GCC LE inferior | RNFL RE superior | RNFL RE inferior | RNFL LE superior | RNFL LE inferior | PD RE | PD LE | OD RE | OD LE |
| f/65 | 73.8 | 71.7 | 74.7 | 77.6 | 77.7 | 83.8 | 83.7 | 74.4 | 1.8 | 1.4 | 3.7 | 3.5 |
| f/35 | 92.7 | 92.7 | 97.5 | 93.1 | 109.2 | 107.6 | 114.2 | 109 | 2.1 | 2.7 | 1.7 | 1.8 |
| f/66 | 88.3 | 89.6 | 90.6 | 93.2 | 95.8 | 107.6 | 103.6 | 108.6 | 2.9 | 3.7 | 3.4 | 3.7 |
| f/48 | 88.9 | 90.2 | 88.1 | 89.3 | 108.9 | 93.5 | 106.2 | 101.3 | 1.2 | 1.7 | 3.1 | 3.7 |
| f/34 | 84.5 | 88.5 | 89.1 | 88.7 | 110.8 | 109.1 | 114.5 | 103.6 | 2.1 | 4.3 | 0.6 | 1 |
| f/67 | 96.1 | 97.6 | 100.7 | 98.9 | 99.9 | 99.6 | 102.9 | 101.4 | 1.5 | 2.3 | 3.1 | 0.5 |
| f/59 | 92.3 | 95.1 | 89.6 | 94.3 | 103.2 | 107.6 | 101.9 | 107.2 | 1.6 | 2.2 | 2.6 | 1.7 |
| f/57 | 98.3 | 98.6 | 96.3 | 103.3 | 97.4 | 104 | 101.5 | 105.3 | 1.4 | 1 | 3.1 | 2.4 |
| f/69 | 93.9 | 90.4 | 89.4 | 88.6 | 110.9 | 93.7 | 98.2 | 93.2 | 1.3 | 1.9 | 3.5 | 4.4 |
| f/55 | 85.1 | 86.2 | 85.1 | 86.5 | 101.1 | 101.5 | 100 | 107 | 1 | 1.5 | 2.4 | 3 |
| f/65 | 91.4 | 90.6 | 106.3 | 96.9 | 104.9 | 119.9 | 105.2 | 110 | 1.6 | 1.9 | 3.6 | 3.4 |
| f/67 | 87.8 | 86.2 | 87.8 | 84.8 | 125 | 117.7 | 114.8 | 107.6 | 2.9 | 2.5 | 3.2 | 3.9 |
| m/74 | 90.1 | 97.3 | 89.1 | 90.1 | 91.9 | 88.6 | 99.4 | 94.6 | 2.3 | 1.5 | 3.9 | 3.9 |
| m/55 | 69.2 | 65.2 | 61.5 | 60.7 | 87.2 | 79 | 83 | 77.5 | 2.3 | 2.8 | 3.1 | 1.6 |
| m/37 | 95.9 | 102.6 | 103.1 | 99.5 | 96.3 | 99.7 | 101.7 | 105.7 | 1.4 | 1.9 | 1.5 | 1.3 |
| m/69 | 83.1 | 81.4 | 84.6 | 82.7 | 101 | 88.3 | 90.5 | 85.9 | 2.1 | 2.5 | 2.9 | 2.2 |
| m/59 | 92.1 | 91.7 | 85.1 | 85.7 | 105.1 | 100.4 | 104.5 | 93.4 | 1.4 | 2.3 | 2.5 | 2.5 |
| m/62 | 75.3 | 79.1 | 74.3 | 76.9 | 81.3 | 79.1 | 81.3 | 79.6 | 1.7 | 3 | 2.7 | 2.8 |
| m/53 | 90.4 | 93.6 | 92.9 | 91.5 | 93.4 | 113.3 | 103.6 | 102.6 | 2 | 1.3 | 3.7 | 2.6 |
| m/65 | 85.2 | 91.6 | 85.2 | 87.5 | 95.6 | 106.7 | 95.3 | 102.9 | 2.3 | 1.6 | 4.5 | 3.7 |
| m/57 | 86.9 | 84.4 | 85.6 | 85.7 | 102.1 | 104.3 | 96 | 100.7 | 1.6 | 1.4 | 3.6 | 3.5 |
| m/72 | 70.8 | 77.6 | 71.6 | 77.2 | 134.9 | 99.8 | 84 | 90.3 | 2.6 | 2.4 | 2.9 | 3.5 |
| m/65 | 99.5 | 105.9 | 93.6 | 100.6 | 93.5 | 115.8 | 102.7 | 115.8 | 1.6 | 1.7 | 4.8 | 3.9 |
| m/68 | 87.3 | 87.5 | 86.8 | 86.6 | 92.5 | 95.9 | 89.3 | 84.5 | 1.3 | 2.3 | 2.8 | 2.7 |
| m/49 | 87.5 | 91.2 | 87.7 | 91.3 | 87.9 | 89.7 | 87.6 | 89.1 | 2.1 | 1.9 | 3.2 | 2.2 |

Table 1. Summary table of values measured in HTGI



Plot 1. Correlation between the GCC superior and the RNFL superior – HTGI patients



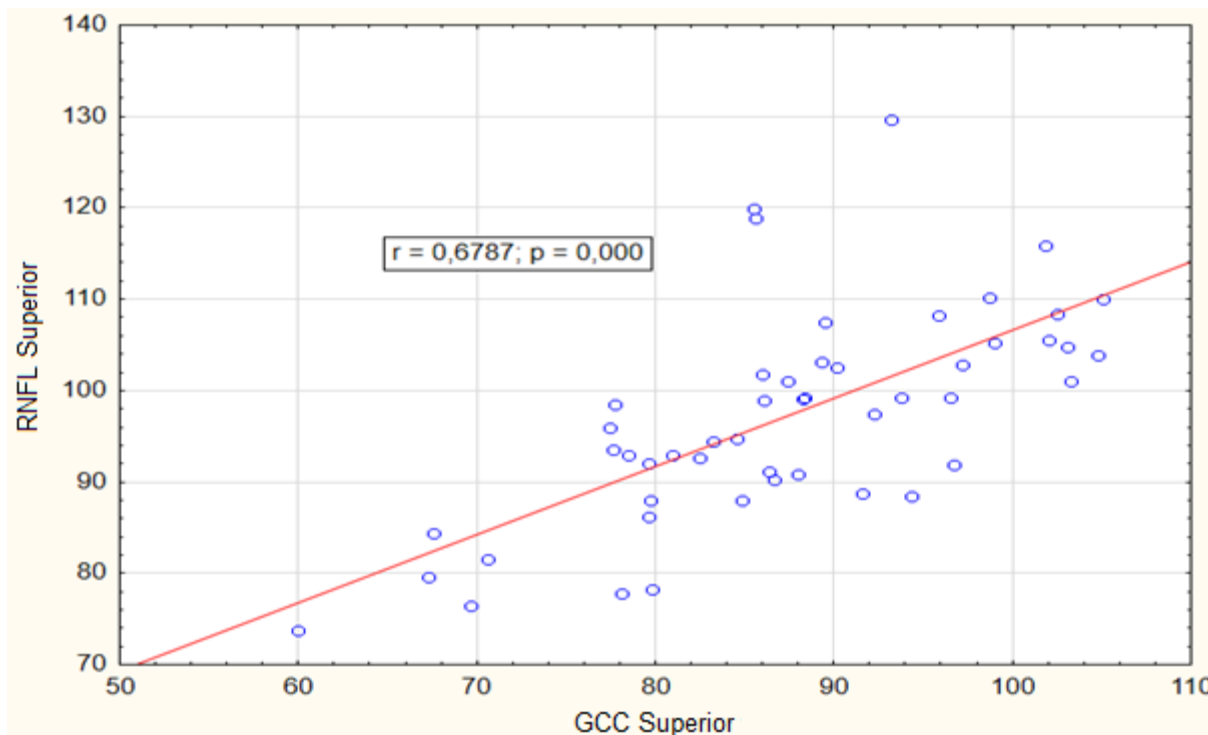
Plot 2. Correlation between the GCC inferior and the RNFL inferior – HTGI patients

In the group of patients with NTG, there was no statistically significant difference between the GCC superior and the GCC inferior values. Similarly, we did not find any statistically significant difference between the RNFL from the upper half of the optic disk versus the RNFL from the lower half.

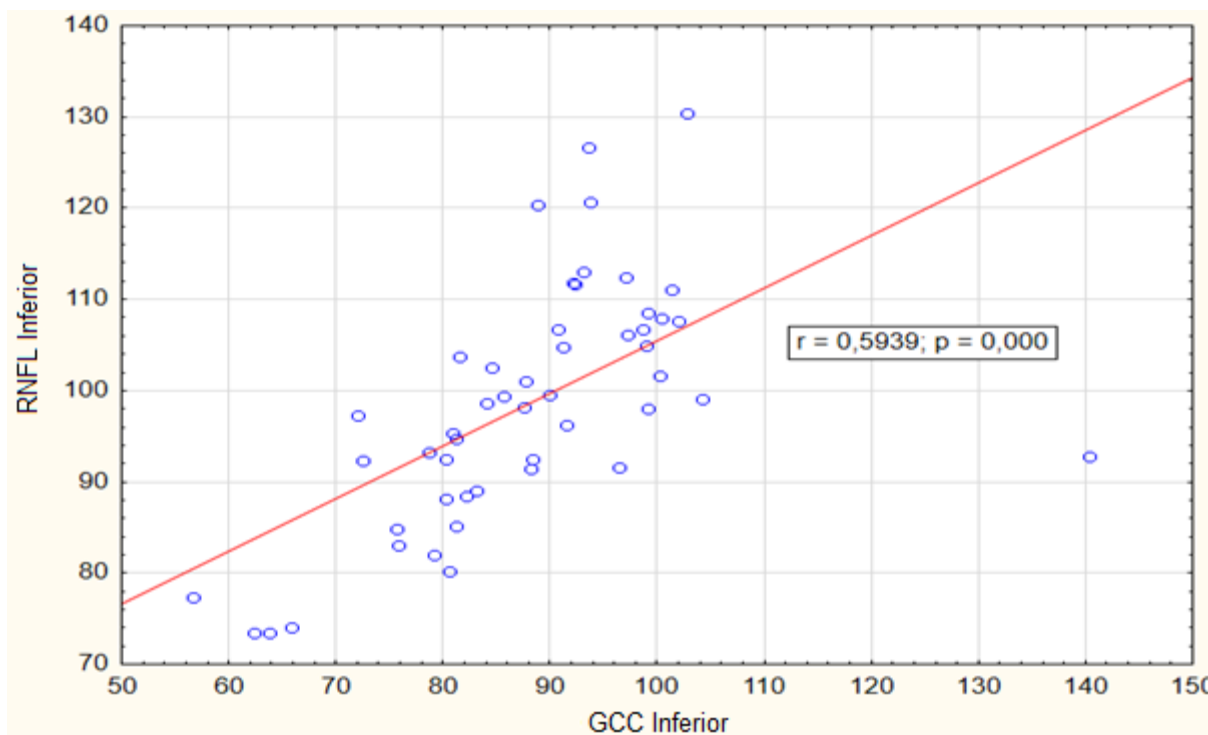
| NTGI | | | | | | | | | | | | |
|------------|-----------------|-----------------|-----------------|-----------------|------------------|------------------|------------------|------------------|-------|-------|-------|-------|
| Sex / year | GCC RE superior | GCC RE inferior | GCC LE superior | GCC LE inferior | RNFL RE superior | RNFL RE inferior | RNFL LE superior | RNFL LE inferior | PD RE | PD LE | OD RE | OD LE |
| f/33 | 79.6 | 72.5 | 80.9 | 80.9 | 92 | 92.3 | 93 | 95.4 | 1.9 | 1.8 | 1.9 | 2.3 |
| f/72 | 83.2 | 81.3 | 78.5 | 80.2 | 94.4 | 94.7 | 92.9 | 92.5 | 1.7 | 1.9 | 4.7 | 4 |
| f/47 | 79.8 | 80.3 | 79.6 | 80.6 | 78.3 | 88.2 | 86.2 | 80.2 | 2.4 | 1.7 | 1.2 | 1.9 |
| f/65 | 88 | 88.2 | 88.4 | 88.3 | 90.9 | 91.4 | 99.3 | 92.5 | 1.2 | 1.7 | 4.4 | 4.8 |
| f/46 | 89.3 | 91.2 | 93.8 | 89.9 | 103.2 | 104.8 | 99.3 | 99.6 | 1.5 | 1.8 | 2.9 | 2.7 |
| f/59 | 86.4 | 90.8 | 84.6 | 81.5 | 91.1 | 106.7 | 94.7 | 103.8 | 2.1 | 2.6 | 3.2 | 3.2 |
| f/75 | 89.5 | 92.2 | 85.6 | 85.6 | 107.4 | 111.9 | 118.8 | 99.4 | 1.9 | 2.3 | 3.2 | 3.6 |
| f/61 | 77.6 | 78.7 | 77.7 | 81.2 | 93.5 | 93.3 | 98.5 | 85.2 | 2.8 | 2.9 | 3.8 | 3.1 |
| f/30 | 99 | 100.4 | 96.7 | 101.9 | 105.3 | 107.9 | 91.9 | 107.7 | 2.6 | 2.6 | 3.4 | 3.6 |
| f/74 | 91.6 | 93.1 | 103.3 | 140.3 | 88.8 | 113 | 101 | 92.8 | 2.4 | 2.8 | 3.9 | 2.9 |
| f/62 | 102 | 97.2 | 103.1 | 98.6 | 105.6 | 106.2 | 104.8 | 106.7 | 1.6 | 1.6 | 3.7 | 3.9 |
| f/71 | 69.7 | 75.6 | 67.6 | 56.6 | 76.5 | 84.8 | 84.4 | 77.3 | 2.8 | 1 | 3.2 | 2.3 |
| f/53 | 77.4 | 62.3 | 92.2 | 91.5 | 96 | 73.4 | 97.5 | 96.3 | 1 | 2.4 | 3.2 | 3.2 |
| f/49 | 82.5 | 84.5 | 88.3 | 87.7 | 92.7 | 102.6 | 99.1 | 101 | 2.4 | 2.3 | 2.2 | 2.2 |
| f/51 | 90.2 | 93.6 | 85.5 | 88.9 | 102.6 | 126.7 | 119.9 | 120.3 | 1.3 | 1.1 | 4.3 | 4 |
| f/25 | 87.4 | 82.2 | 86.1 | 84.1 | 101.1 | 88.4 | 98.9 | 98.6 | 1.2 | 1.1 | 1.3 | 1.2 |
| f/68 | 98.7 | 99.2 | 95.9 | 93.8 | 110.2 | 108.5 | 108.3 | 120.7 | 2.1 | 2.9 | 3.8 | 3.6 |
| m/47 | 96.5 | 100.3 | 104.8 | 98.9 | 99.3 | 101.7 | 103.9 | 104.9 | 1.7 | 1.3 | 3.3 | 2.9 |
| m/65 | 84.8 | 83.1 | 79.7 | 75.8 | 88 | 89 | 88 | 83 | 2.6 | 2.5 | 4.1 | 2.6 |
| m/69 | 67.3 | 63.8 | 60 | 65.9 | 79.6 | 73.4 | 73.7 | 74 | 5 | 5 | 2.9 | 0.5 |
| m/67 | 93.2 | 97 | 86 | 92.4 | 129.6 | 112.5 | 101.8 | 111.7 | 2.3 | 3 | 2.6 | 2.3 |
| m/51 | 94.3 | 96.4 | 86.6 | 87.6 | 88.5 | 91.6 | 90.3 | 98.2 | 2 | 1.4 | 2.8 | 1.7 |
| m/59 | 78.1 | 79.1 | 70.6 | 72 | 77.8 | 82 | 81.5 | 97.3 | 2.5 | 2.4 | 2.7 | 2.3 |
| m/32 | 101.8 | 102.7 | 105.1 | 101.3 | 115.9 | 130.4 | 110 | 111 | 1.3 | 1.3 | 2.1 | 1.7 |
| m/54 | 102.5 | 104.2 | 97.2 | 99.1 | 108.4 | 99.1 | 102.9 | 98.1 | 2 | 1.6 | 2.4 | 3.3 |

Table 2. Summary table of values measured in NTGI

With regard to the correlation between the GCC and RNFL values in the upper halves of the retina in NTG, we found medium-strong and statistically significant positive correlation ($r=0.67$), i.e. the higher GCC, the higher RNFL. See Plot 3. Values from the lower retinal halves showed similar behaviour ($r=0.59$). See Plot 4.



Plot 3. Correlation between the GCC superior and the RNFL superior – NTGI patients



Plot 4. Correlation between the GCC inferior and the RNFL inferior – NTGI patients

By comparison of the GCC, RNFL and changes in visual fields, we found medium-strong correlation only in patients with NTG between PD and GCC superior ($r=-0.41$, $p=0.003$) and PD and RNFL superior ($r=-0.4$, $p=0.005$) and also between PD and RNFL inferior ($r=-0.3$, $p=0.03$).

In HTG, we did not find any statistically significant correlation.

Discussion

There is a relatively high abundance of publications on the GCC and RNFL in hypertension glaucomas. Fewer publications are available on HTG versus NTG. In HTG, where the ganglion cells' damage occurs diffusely over the entire retina, we did not expect any differences in thickness of the GCC and RNFL in the altitudinal halves. However, we demonstrated that in our work as well. In HTG, the loss of ganglion cells is accompanied by RNFL damage. This fact was also confirmed with medium-strong correlation. In NTGI, where the retinal ganglion cells are relatively undamaged, we did not find any differences in thickness of the GCC and RNFL in the altitudinal halves. We observed medium-strong correlation when comparing GCC, RNFL and PD in the upper half and also between RNFL from the lower half and PD. In HTGI, we did not observe any similar relationship between GCC, RNFL and PD.

Our hypothesis is in line with the results in Kim et al. [10], where the GCC loss in the NTG group was more localised compared with the diffuse GCC loss in the POAG group. Perimacular GCC parameters could be a good alternative or supplement to peripapillary RNFL measurements for diagnosis and research in patients with NTG. Similar results are also reported in Firat et al. [5], where SD-OCT evaluation results suggest higher GCC and RNFL parameters for NTG than POAG, and in Gracitelli et al. [7], where average RNFL thickness in eyes with NTGI was 18.7 μm thinner than in eyes with HTG.

Our hypothesis also corresponds with the results of Vidinov et al. [20], who demonstrated that changes in the RNFL prevailed over those in the GCC in 56 % of normal-tension glaucoma patients. In 58 % of the glaucoma suspects, there were no changes in the perimetry results, as well as with OCT. In 42 % of the subjects, pathological changes in the GCC map preceded those of the RNFL. In patients with HTG, an almost linear correlation was found between the RNFL changes and GCC alterations.

All our patients had an early stage disease. Therefore, we expected statistically significant correlation only in NTG. The results of our work confirmed our expectations.

Another opinion is represented by Distante et al. [3], who compared the GCC, RNFL and changes in visual fields and found a medium-strong correlation in different stages of HTG. A similar finding was recorded by Rao et al. [16], where most of the RNFL and GCC parameters had better sensitivities and negative likelihood ratios to diagnose GON compared with SAP.

GCC and RNFL examinations are structural imaging techniques that do not represent any functional state of the retinal ganglion cells and their axons. The ganglion cell first collapses and subsequently dies, as soon as the basic cause of the condition oversteps the given time limit. Therefore, it is possible to observe the PERG decrease (pattern electroretinogram) before any structural changes appear. This fact was also demonstrated in Bowd et al. [2], where the PERG amplitude is significantly (but weakly) associated with macular GCC thickness, RNFL thickness, and macular thickness.

Conclusion

Examination of the GCC, RNFL and PD showed medium-strong correlation only in patients with NTG. These conclusions indicate the existence of two different diseases which also require different treatments.

The study protocol was approved by the local Ethics Committee and the study was performed in accordance with Good Clinical Practice and the Declaration of Helsinki.

Conflict of interest statement

The authors state that there are no conflicts of interest regarding the publication of this article.

Acknowledgements

Supported in part by research project P37/07 (Prvouk) of the Ministry of Health, Prague, Czech Republic

References

1. Araie M., Yamagami J., Suzuki Y.: Visual field defects in normal-tension and high-tension glaucoma. *Ophthalmology*, 1993;100: 1808–1814.
2. Bowd C, Tafreshi A, Zangwill LM, Medeiros FA, Sample PA, Weinreb RN: Pattern electroretinogram association with spectral domain OCT structural measurements in glaucoma. *Eye (Lond)*, 2011;25:224-232.
3. Distante P, Lombardo S, Verticchio Vercellin AC, Raimondi M, Rolando M, Tinelli C, Milano G: Structure/Function relationship and retinal ganglion cells counts to discriminate glaucomatous damages. *BMC Ophthalmol*, 2015 Dec 29;15:185. doi: 10.1186/s128860150177x.
4. Eid TE., Spaeth GL., Moster MR., Augburger JJ: Quantitative differences between the optic nerve head and peripapillary retina in low-tension glaucoma and high-tension primary open-angle glaucoma. *Am J Ophthalmol*, 1997;124: 805-813.
5. Firat PG, Doganay S, Demirel EE, Colak C: Comparison of ganglion cell and retinal nerve fiber layer thickness in primary open-angle glaucoma and normal tension glaucoma with spectral-domain OCT. *Graefes Arch Clin Exp Ophthalmol*. 2013;251:831-638.
6. Flammer J., Prünke C.: Ocular vasospasm. 1: Functional circulatory disorders in the visual system, a working hypothesis. *Klin Monbl Augenheilkd*, 1991;1981: 411-412.
7. Gracitelli CP, Moreno PA, Leite MT, Prata TS: Identification of the Most Accurate Spectraldomain Optical Coherence Tomography Parameters in Eyes With Early HighTension and LowTension Glaucoma. *J Glaucoma*, 2016 Mar 4. [Epub ahead of print]
8. Chang M, Yoo C, Kim SW, Kim YY: Retinal Vessel Diameter, Retinal Nerve Fiber Layer Thickness, and Intraocular Pressure in Korean Patients with Normal-Tension Glaucoma. *Am J Ophthalmol*, 2011;151: 100-105.
9. Cheng HC, Chan CM, Yeh SI, Yu JH, Liu DZ: The Hemorheological Mechanisms in Normal Tension Glaucoma. *Curr Eye Res*, 2011;36: 647-653.
10. Kim NR, Hong S, Kim JH, Rho SS, Seong GJ, Kim CY: Comparison of macular ganglion cell complex thickness by Fourier-domain OCT in normal tension glaucoma and primary open-angle glaucoma. *J Glaucoma*. 2013;22:133-139.
11. Lešták, J., Nutterová, E., Pitrová, Š., Krejčová, H., Bartošová, L., Forgáčová, V.: High tension versus normal tension glaucoma. A comparison of structural and functional examinations. *J Clinic Exp Ophthalmol* 2012, S:5, <http://dx.doi.org/10.4172/2155-9570.S5-006> ISSN: 2155-9570

12. Lestak J., Nutterova E., Bartosova L., Rozsival P.: The Visual Field in Normal tension and Hypertension Glaucoma. *International Journal of Scientific Research*, 2014;3: 49-51.
13. Lester M., De Feo F., Douglas GR.: Visual field loss morphology in high-and normal-tension glaucoma. *J Ophthalmol*, 2012; 327326. Epub 2012: Feb 8.
14. Okuno T., Sugiyama T., Kojima S., Nakajima M., Ikeda T.: Diurnal variation in microcirculation of ocular fundus and visual field change in normal-tension glaucoma. *Eye (Lon)*, 2004;18: 697-702.
15. Plange N., Remky A., Arend O.: Colour Doppler imaging and fluorescein filling defects of the optic disc in normal tension glaucoma. *Br J Ophthalmol*, 2003;87: 731-736.
16. Rao HL, Yadav RK, Addepalli UK, Begum VU, Senthil S, Choudhari NS, Garudadri CS. Comparing spectraldomain optical coherence tomography and standard automated perimetry to diagnose glaucomatous optic neuropathy. *J Glaucoma*. 2015;24:69-74.
17. Schwenn O., Troost R., Vogel A., Grus F., Beck S., Pfeiffer N.: Ocular pulse amplitude in patients with open angle glaucoma, normal tension glaucoma, and ocular hypertension. *Br J Ophthalmol*, 2002;86: 981-984.
18. Shin IH., Kang SY., Hong S., Kim SK., Seong GJ., Ma KT., Kim CY.: Comparison of OCT and HRT findings among normal tension glaucoma, and high tension glaucoma. *Korean J Ophthalmol*, 2008;22: 236-241.
19. Takeyama A, Kita Y, Kita R, Tomita G: Influence of axial length on ganglion cell complex (GCC) thickness and on GCC thickness to retinal thickness ratios in young adults. *Jpn J Ophthalmol*. 2014;58:86-93.
20. Vidinova CN, Gouguchkova PT, Vidinov KN: Ganglion Cell Complex Map for Detecting Early Damage in High Tension and Normal Tension Glaucoma. *Klin Monbl Augenheilkd*. 2016;233:72-78.