

Functional magnetic resonance imaging following epimacular and internal limiting membrane peeling – ipsilateral and contralateral findings

Jan Lestak, Bohdana Kalvodova, Ivan Karel, Jaroslav Tintera

Purpose. The purpose of this study was to find out whether peeling of the epimacular membrane (EMM) and internal limiting membrane (ILM) for symptomatic lamellar macular hole (LMH), causes impairment of the visual cortex.

Patients and Methods. This pilot study consisted of 8 eyes of 4 patients (2 females and 2 males), mean age 69.25 years (60-83 years), who underwent pars plana vitrectomy and EMM and ILM peeling in one eye for lamellar macular hole. The second eye remained intact. The patients had no other ophthalmological or neurological disease. The control group consisted of 20 eyes of 10 healthy people (8 females and 2 males), mean age 52 years (34-65 years). In all of them, we performed functional magnetic resonance imaging (fMRI) of the brain to the visual paradigm (black and white chess-board of 25.8 x 16.2 degrees in size), as well as in patients 3-4 years following the surgery. For statistical processing, we used ANOVA and multiple regression for adjustment for the age of patients.

Results. In all patients, we recorded a decrease in fMRI activity of the brain following stimulation of the eye in which surgical intervention was performed. The fMRI values using ANOVA (without adjustment for age) were significantly different between groups ($P < 0.001$). Following adjustment for age and the use of multiple regression, the fMRI values in the operated eyes were lower by 4142.39 vs the control eyes. In the group of unoperated eyes, the fMRI values were lower by 2807.39 vs the control eyes. Therefore, the results did not differ very much from the results without adjustment.

Conclusion. In patients with symptomatic partial macular defect following EMM and ILM peeling, we recorded a significant decrease of the fMRI activity of the brain following stimulation of the operated eye, compared to the control group. We also found a decrease in activity in fMRI following stimulation of the contralateral eye. These findings lead us to the conclusion that EMM and ILM peeling may cause secondary impairment of the visual centres in the brain, not only on the side of the surgical intervention, but also on the contralateral side.

Key words: lamellar macular hole, macular pseudohole, peeling of EMM and ILM, fMRI, ipsilateral, contralateral finding

Received: June 21, 2019; Accepted: August 30, 2019; Available online: September, 26, 2019

<https://doi.org/10.5507/bp.2019.044>

© 2019 The Authors. This is an open access article licensed under the Creative Commons Attribution License (<https://creativecommons.org/licenses/by/4.0/>).

Eye Clinic, Faculty of Biomedical Engineering, Czech Technical University in Prague, Czech Republic

Corresponding author: Jan Lestak, e-mail: lestak@seznam.cz

INTRODUCTION

The Müller glial cells pass across the full thickness of the retina and cover all the retinal cells and their projections. Their internal projections are connected in the internal limiting membrane (ILM). This morphological relationship is reflected in the number of functional interactions between the retinal neurons and the Müller cells, including the extracellular ion homeostasis and transformation of glutamate. Müller cells are key mediators in the protection of neurons, especially by release of the basic fibroblast growth factor, uptake and degeneration of excitotoxic glutamate and secretion of antioxidative glutathione. During hypoxic conditions, neovascularisation is mediated by the Müller cells released from the vascular endothelial growth factor and by transformation of the growth factor, beta or by direct contact with the endothelial cells¹.

Peeling of the retinal ILM appeared to be beneficial in improving the anatomical success of surgical therapy of symptomatic macular defects²⁻⁷. Despite this positive

information, the question whether peeling can impair eye function remains under discussion. There is no doubt that removal of part of the Müller cells causes impairment not only of the Müller cells but it also impairs the metabolic processes in the retina, especially in the layer of glial cells and their fibres. It is also important to emphasise that in the umbo of the foveola, there are only cones and their fibres together with the Müller cells. Removal of the ILM may also cause impairment of the fibres of the cones.

While most studies are focused on visual acuity or retinal function following ILM and EMM peeling, there is no information available on its impact on the visual cortex. In a previous study, we aimed precisely at this issue and found a statistically significant decrease in functional magnetic resonance (fMRI) results following stimulation of the operated eye following peeling, compared to the second eye⁸. As in an experiment following ipsilateral retinal or optic nerve damage, the glial tissue is activated and damage to the ganglion cells in the retina of the intact eye occurs as well, the authors do not recommend the use of the intact eye as a control eye⁹⁻¹².

Table 1. Summary table of all patients.

No.	Sex/Age	VA before RE/LE	VA after RE/LE	fMRI		OCT	Clinical diagnosis	Peeling	Years after surgery
				RE	LE				
1.	F/66	1.0/0.1	1.0/0.6	4 900	1 600	EMM	EMM	LE	4
2.	F/68	0.3/0.6	0.4/0.6	4 600	5 450	LMH	LMH	RE	4
3.	M/60	1.0/0.2	1.0/0.5	2 200	2 060	LMH	EMM	LE	3
4.	M/83	1.0/0.8	1.0/0.8	3 950	2 900	MPH	EMM	LE	4

EMM-epimacular membrane, LMH-lamellar macular hole, MPH-macular pseudohole.

Therefore, the purpose of our study was not only to compare the results of the activity of fMRI following stimulation of an eye following EMM and ILM peeling with the control group, but also to compare the intact eye with a control group.

Cohort

The pilot study consisted of 8 eyes of 4 patients (2 females and 2 males), mean age 69.25 years (60-83 years), who underwent pars plana vitrectomy and EMM and ILM peeling in one eye. The second eye remained intact. The patients had no other ophthalmological or neurological disease. The control group consisted of 20 eyes of 10 healthy people (8 females and 2 males) of mean age 52 years (34-65 years). In all of them, we performed functional magnetic resonance imaging (fMRI) of the brain to the visual paradigm (black and white chessboard of 25.8×16.2 degrees in size), as well as in patients 3-4 years following the surgery.

For determination of LMH and MPH, we used the definitions referred to in publications^{13,14}.

Surgical technique

Under local anaesthesia, patients underwent 3-port triamcinolone-supported (TA) 23-gage PPV with a separation and removal of the posterior vitreous cortex. In all eyes, we applied approximately 0.5 mL of TA to the centre of the vitreous cavity. Following suction of the vitreous humour, 0.15% solution of trypan blue (MembraneBlue, D.O.R.C International, Rotterdam, the Netherlands) was used for visualisation of the EMM and ILM at simultaneous stopping of the infusion. Following 60 s, the infusion was restored and the dye was removed. We used special micro tweezers for peeling of the EMM and ILM. The ILM was removed in all eyes, although sometimes unintentionally together with the EMM.

Functional MRI

All fMRI measurements were performed using the Philips Achieva TX SERIES system with magnetic pole of 3 Tesla according to our own methodology¹⁵.

RESULTS

Visual acuity was improved in 3 eyes, 3-4 years post-surgery and remained unchanged in 1 eye.

All eyes which underwent surgical intervention showed lower activity during the fMRI examination compared to the control intact eye (Table 1 and 2).

In all patients, we recorded a decrease in fMRI activity of the brain following stimulation of the eye where surgical intervention was performed. We also found a similar decrease following stimulation of the unoperated, healthy eye (4125 ± 1425). The fMRI values using ANOVA (without adjustment for age) in all groups showed a significant difference ($P < 0.001$). Following adjustment for age and the use of multiple regression, the fMRI values in the operated eyes were approximately lower by 2807.39 vs the control eyes. The results were not very different from the results without adjustment.

DISCUSSION

Reports on fMRI examination following EMM and ILM peeling in PMH and LMH are missing from the literature. Trans-synaptic neuronal degeneration and impairment of the ganglion cells of the visual cortex can be expected following impairment of the ganglion cells of the retina. This is also shown in studies on hypertensive glaucoma^{15,16} and age-related macular degeneration^{17,18}.

We also anticipated a similar mechanism of possible damage to the visual cortex in this study. During impairment of the ganglion cells of the retina, either directly via impairment of their axons or indirectly via the Müller cells of the retina, impairment of the ganglion cells of the

Table 2. The table shows the fMRI values in the control group.

Sex/Age	RE	LE
F-34	8 880	10 710
F-48	7 212	10 013
F-50	6 627	11 730
F-46	5 882	5 847
F-49	9 783	6 754
F-50	3 537	2 256
F-60	7 628	6 011
F-65	6 780	6 415
M-58	8 255	6 881
M-60	10 580	6 792

The mean value was 7428 ± 2366 .

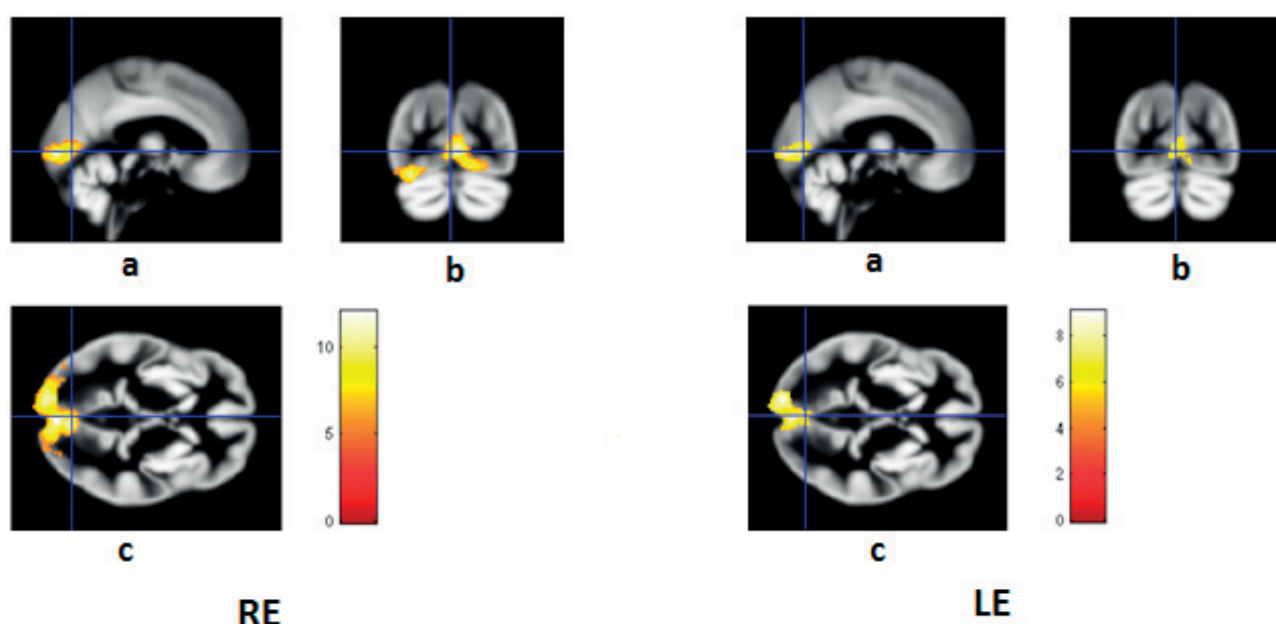


Fig. 1. Patient no. 1. Left eye Right eye. fMR 4900 voxel. Left eye. fMR 1600 voxel. Sagittal (a), coronal (b) and transverse (c) sections.

visual cortex may occur via transneuronal degeneration at some period of time.

Possible damage to the retina following PPV with peeling has been documented by a number of studies, which refer to the anatomical and functional changes at various timepoints following the procedure. Baba et al.¹⁹ found a reduction of the layer of ganglion cells using OCT 3 to 6 months following PPV with peeling. Similar conclusions were reached by Kumagai et al.²⁰. The authors examined 24 eyes following ILM peeling for macular hole and found a significant reduction of the mean retinal width one month post-surgery. This reduction continually decreased during the 24 months of follow-up, except for the nasal retinal area where the procedure was not done.

On the other hand, Sevim and Sanisoglu found no difference in the width of the layer of the ganglion cells before and after surgery, subsequent to surgery of the macular hole with ILM peeling and without peeling, after 6 months²¹.

Clark et al. studied changes in the layer of nerve fibres following peeling for the macular hole. They found oedema in the layer of nerve fibres during the first month following surgery with regression of oedema after two months. This finding had no effect on visual acuity²².

In this respect, the study by Lesnik Oberstein et al., who performed immunological examination of the epi-retinal membrane using peeling, deserves attention. In all 32 cases, they found nervous fibres of the ganglion cells labelled with anti-neurofilament²³.

Tsuiki et al. studied the functional changes following PPV with ILM peeling. They retrospectively studied the perimetric findings in 140 eyes in which PPV with peeling of the ILM (assisted ICG) was performed for macular hole and they found nasal defects in 11 eyes, temporal defects in 7 eyes in the visual field and concentric narrowing in 1 eye²⁴.

Tadaoni et al., using microperimetry, examined 16 eyes following surgery of idiopathic macular hole. In 8 eyes with peeling, they found a higher increase of sensitivity vs 8 eyes where surgery was performed without ILM peeling²⁵.

Using a focal macular electroretinogram 6 weeks and subsequently 6 months after the successful closure of the hole, Terasaki et al. found that the percentage increase in amplitude of the b wave 6 months following the procedure was significantly higher in the group without peeling (44.0%) vs in the group with peeling (15.0%, $P=0.037$) (ref.²⁶).

Although the above studies document possible damage to the retina during ILM peeling, opinion in favour of peeling predominates. The economical aspect of peeling must also be emphasised, as it offers more favourable cost-effectiveness, and therefore increases the primary success of surgery and decreases the probability of re-operation²⁷. During PPV and peeling of the ILM with intravitreal administration of triamcinolone-acetate, the possible cytotoxic effects on the ganglion cells of the retina must be considered²⁸.

In our patients, TA was always thoroughly removed during vitrectomy. We consider its unfavourable effect on the retinal structures as being very unlikely.

Studies are missing on anterograde transneuronal degeneration with regard to time to reach cortical ganglion cells after retinal stimulus. We can only speculate on the period of time being longer than 12 months. We performed fMRI 3-4 years following PPV with peeling and all patients had a lower activity of fMRI following light stimuli in both eyes, although more noticeably in the operated eye. These results lead us to the confirmation of our original assumption that peeling causes damage to the ganglion cells of the visual cortex of the brain, not only on the side of the peeling but also on the contralateral side.

We must note that we used a very small group in our study and we are aware of this factor. On the other hand, there are very few studies aimed at fMRI in clinical ophthalmology and the groups of patients are smaller than 10 patients.

CONCLUSION

In patients with symptomatic partial macular defect following EMM and ILM peeling, we recorded a significant decrease in the activity in fMRI of the brain following stimulation of the operated eye, compared to the control group. We also found a decrease in activity in fMRI following stimulation of the contralateral eye. These findings lead us to the conclusion that EMM and ILM peeling may cause secondary impairment of the visual centres in the brain, not only on the side of the surgical intervention but also on the contralateral side.

ABBREVIATIONS

EMM, Epimacular membrane; fMRI, Functional magnetic resonance imaging; ICG, Indocyanine green; ILM, Internal limiting membrane; LMH, Lamellar macular hole; MPH, Macular pseudohole; OCT, Optical coherence tomography; PPV, Pars plana vitrectomy; TA, Triamcinolone acetate.

Conflict of interest statement: The authors declare no conflicts of interest regarding the publication of this article.

Author contributions: JL, BK, IK, JT: manuscript writing, final approval; JL, BK, JT: literature search, data analysis.

REFERENCES

- Bringmann A, Reichenbach A. Role of Muller cells in retinal degenerations. *Front Biosci* 2001;6:E72-92.
- Garretson BR, Pollack JS, Ruby AJ, Drenser KA, Williams GA, Sarrafzadeh R. Vitrectomy for a symptomatic lamellar macular hole. *Ophthalmology* 2008;115(5):884-6.
- Engler C, Schaal KB, Höh AE, Dithmar S. Surgical treatment of lamellar macular hole. *Ophthalmologie* 2008;105(9):836-9.
- Androudi S, Stangos A, Brazitikos PD. Lamellar macular holes: tomographic features and surgical outcome. *Am J Ophthalmol* 2009;148:420-6.
- Casparis H, Bovey EH. Surgical treatment of lamellar macular hole associated with epimacular membrane. *Retina* 2011;31(9):1783-90.
- Su J, Liu X, Zheng L, Cui H. Vitrectomy with internal limiting membrane peeling vs no peeling for Macular Hole-induced Retinal Detachment (MHRD): a meta-analysis. *BMC Ophthalmol* 2015;15:62. doi: 10.1186/s12886-015-0048-5
- Veith M., Straňák, Z., Penčák, M. et al.: Chirurgické řešení idiopatické makulární díry 25-Gauge pars plana vitrektomií s peelingem vnitřní limitující membrány asistované brilantovou modří a plynovou tamponádou. *Cesk Slov Oftalmol* 2015;71:170-4. (In Czech)
- Lešták J, Tintěra J, Kalvoda J, Kalvodov8 B, Karel I. FMRI after internal limiting membrane peeling for symptomatic lamellar macular hole and macular pseudohole surgery. *International Journal of Applied Research* 2014;4:379-82.
- Bodeutsch N, Siebert H, Dermon C, Thanos S. Unilateral injury to the adult rat optic nerve causes multiple cellular responses in the contralateral site. *J Neurobiol* 1999;38(1):116-28.
- Panagis L, Thanos S, Fischer D, Dermon CR. Unilateral optic nerve crush induces bilateral retinal glial cell proliferation. *Eur J Neurosci* 2005;21(8):2305-9.
- Ramírez AI, Salazar JJ, de Hoz R, Rojas B, Gallego BI, Salinas-Navarro M, Alarcón-Martínez L, Ortín-Martínez A, Avilés-Trigueros M, Vidal-Sanz M, Triviño A, Ramírez JM. Quantification of the effect of different levels of IOP in the astroglia of the rat retina ipsilateral and contralateral to experimental glaucoma. *Invest Ophthalmol Vis Sci* 2010;51(11):5690-6.
- Cen LP, Han M, Zhou L, Tan L, Liang JJ, Pang CP, Zhang M. Bilateral retinal microglial response to unilateral optic nerve transection in rats. *Neuroscience* 2015;17:311:56-66.
- Haouchine B, Kasein P, Tadayoni R, Erginay A, Gaudric A. Diagnosis of macular pseudoholes and lamellar macular holes by optical coherence tomography. *Am J Ophthalmol* 2004;138:732-9.
- Witkin AJ, Ko,TH, Fujimoto JG, Schuman JS, Bajkal CR, Rogers,AH, Reichel,E, Duker JS. Redefining lamellar holes and vitreomacular interface: An Ultrahigh-resolution optical coherence tomography study. *Ophthalmology* 2006;113:388-97.
- Lešták J, Tintěra J. Funkční magnetická rezonance u vybraných očních onemocnění. *Cesk Slov Oftalmol* 2015;71:127-33. (In Czech)
- Duncan RO, Sample PA, Weinreb RN, Bowd C, Zangwill LM. Retinotopic Organization of Primary Visual Cortex in Glaucoma: Comparing fMRI Measurements of Cortical Function with Visual Field Loss. *Prog Retin Eye Res* 2007;26(1):38-56.
- Nguyen TH, Stievenart JL, Saucet JC, Le Gargasson JF, Cohen YS, Pelegrini-Issac M, Burnod Y, Iba-Zizen MT, Cabanis EA. Cortical response to age-related macular degeneration (part I). Methodology and subject specificities. *J Fr Ophtalmol* 2004a;27(11):65-71.
- Lestak J, Tintera J, Karel I, Svata Z, Rozsival P. FMRI in Patients with Wet Form of Age-Related Macular Degeneration. *Neuro-Ophthalmology* 2013;37(5):192-7.
- Baba T, Yamamoto S, Kimoto R, Oshitari T, Sato E. Reduction of thickness of ganglion cell complex after internal limiting membrane peeling during vitrectomy for idiopathic macular hole. *Eye (Lond)* 2012;26(9):1173-80.
- Kumagai K, Hangai M, Larson E, Ogino N. Progressive changes of regional macular thickness after macular hole surgery with internal limiting membrane peeling. *Invest Ophthalmol Vis Sci* 2013;54(7):4491-7.
- Sevim MS, Sanigoglu H: Analysis of retinal ganglion cell complex thicketness after Brilliant Blue-assisted vitrectomy for idiopathic macular holes. *Curr Eye Res* 2013;38(1):180-4.
- Clark A, Balducci N, Pichi F, Veronese C, Morara M, Torrazza C, Ciardella APOD. Swelling of the arcuate nerve fiber layer after internal limiting membrane peeling. *Retina* 2012; 32(8):1608-13.
- Lesnik Oberstein SY, Lewis GP, Chapin EA, Fisher SK. Ganglion cell neurites in human idiopathic epiretinal membranes. *Br J Ophthalmol* 2008;92(7):981-5.
- Tsuiki E, Fujikawa A, Miyamura N, Yamada K, Mishima K, Kitaoka T: Visual field defects after macular hole surgery with indocyanine green-assisted internal limiting membrane peeling. *Am J Ophthalmol* 2007;143(4):704-5.
- Tadayoni R, Svorenova I, Erginay A, Gaudric A, Massin P. Decreased retinal sensitivity after internal limiting membrane peeling for macular hole surgery. *Br J Ophthalmol* 2012;96:1513-6.
- Terasaki H, Miyake Y, Nomura R, Piao CH, Hori K, Niwa T, Kondo M. Focal macular ERGs in eyes after removal of macular ILM during macular hole surgery. *Invest Ophthalmol Vis Sci* 2001;42(1):229-34.
- Spiter Cornish K, Lois N, Scott N, Burr J, Cook J, Boachie C, Tadayoni R, la Cour M, Christensen U, Kwok A: Vitrectomy with internal limiting membrane (ILM) peeling versus vitrectomy with no peeling for idiopathic full-thickness macular hole (FTMH). *Cochrane Database Syst Rev* 2013 5;6:CD009306
- Jaissle GB, Bartz-Schmidt KU, Szurman P. Optic atrophy subsequent to epiretinal triamcinolone deposits in an eye following inner limiting membrane peeling. *Ophthalmologie* 2008;105(6):575-7.